

Case Report

Unilateral Microphthalmos with Associated Retina Detachment in A Nigerian Child

CO Omolase, MY Majekodunmi, AK Akinwalere, BO Omolase

Pak J Ophthalmol 2011, Vol. 27 No. 1

See end of article for authors affiliations

Correspondence to:
Omolase Charles Oluwole
Federal Medical Centre
PMB 1053, Owo, Ondo State
Nigeria

Received for publication
August' 2010

This report is that of a two year old Nigerian child who presented to the eye clinic of Federal Medical Centre, Owo in June, 2010 on account of small left eye noticed since birth. Examination carried out revealed no perception of light in the left eye, left microphthalmos with associated retinal detachment. The right eye was normal. Systemic examination did not reveal any associated congenital anomaly. There is no history of similar occurrence in her family but the mother had a febrile illness with associated rashes suspicious of rubella in the course of the pregnancy. Retina surgery was not advised in view of the no perception of light in the affected eye. There is need for adequate antenatal care to prevent some congenital anomalies.

Microphthalmos is a rare congenital anomaly of the eye. It is a developmental arrest of ocular growth¹. Microphthalmos means small eye. The total axial length of the eye in microphthalmos is at least 2 standard deviation below age-similar control¹. The reduction in the axial length of the eyes is due to stunted growth of the anterior or posterior segments of the eye or both segments. Microphthalmos can be classified into simple/pure microphthalmos in which case there is absence of major ocular malformations and complex in which there are ocular abnormalities². Microphthalmos usually ranges from mild to extreme reduction of total axial length of the eyes³. Most cases of non-syndromic microphthalmos are sporadic⁴⁻⁶. Environmental factors can also be responsible for non syndromic microphthalmos⁷. Microphthalmos has been reported to be associated with other ocular abnormalities like congenital cataract, sclerocornea and dysgenesis of the anterior chamber⁸.

Posterior microphthalmos is a form of microphthalmos in which there is reduction of total axial length of the eyes, normal cornea diameter resulting in high hypermetropia and a papillomacular retinal fold^{2,9,10}. It differs from nanophthalmos in which there

is microphthalmos, microcornea and a tendency towards uveal effusion.

We highlight in this case report the case of a two year old child who presented with left microphthalmos associated with retina detachment. There are few reports of similar presentation in this part of the world.

CASE HISTORY

A two year old Nigerian girl was brought to our eye clinic in June, 2010 with the history of small left eye noticed by the mother since birth. There was no antecedent trauma. Pregnancy history revealed that mother had rashes that were suggestive of rubella at the seventh month of pregnancy and she was managed at a private hospital. The mother had full term pregnancy delivered via spontaneous vagina delivery. Perinatal and post natal periods were uneventful. She is the third of three children in a monogamous family and there is no history of similar occurrence in her siblings. Examination of the eyes revealed that the patient could track light with the right eye while she could not perceive light with the left eye. The anterior and posterior segments of the

right eye were essentially normal. However there was microphthalmos and cyclotropia of the left eye. The vertical and horizontal diameters of the right eye were 10.5mm and 11mm respectively while it was 6mm vertically and 7mm horizontally on the left. The lens of both eyes was clear. Dilated funduscopy done on the left eye revealed extensive retina detachment involving the macula while the fundus on the right was essentially normal. B scan ultrasonography done revealed an AP diameter of 19mm on the right and 12mm on the left. The ultrasonography confirmed retina detachment on the left side.

General and systemic examination done did not reveal any other anomaly.

The condition of the left eye was explained to the mother in details. However retinal surgery was not advised in view of the inability of the left eye to perceive light. The child was however to come for periodic review by the Ophthalmologist and follow up by the Paediatricians.

DISCUSSION

In congenital microphthalmos, the orbital growth is deficient.¹¹ It can thus lead to facial asymmetry. The overall prevalence of congenital microphthalmos and nanophthalmos has been estimated at 1 to 1.5 per 10,000 births^{11,12}. Microphthalmos is unilateral in 75% of cases¹¹. No consistent hereditary basis has been found¹¹. Extrinsic causes such as maternal rubella or environmental teratogens are often suspected¹³. Other infectious agents such as toxoplasmosis, herpes and cytomegalovirus have been reported to be associated with microphthalmos^{14,15}. The case reported was said to be the first in nuclear and extended family of the patient. However, the history of flu-like illness with associated rashes and fever in the mother at the seventh month of pregnancy was suggestive of rubella. The authors could not be categorical on this suspicion in view of the fact that relevant serological investigations were not done at the Private hospital where the mother of the patient sought treatment. Was the possibility to do rubella serology in mother/child to substantiate suspicion (Diagram). This brings to force the importance of antenatal care in preventing complications arising in course of pregnancy which could adversely affect the baby after delivery. The late presentation of the child could also have contributed to the poor prognosis of restoration of vision in the affected eye.

Microphthalmos with associated retina detachment is said to be rare and this assertion is buttressed by the fact that the authors are not aware of similar reports in Nigeria. However Chen et al reported a case of microphthalmos with associated retina detachment and choroidal coloboma in a 28 year old patient in Taiwan who complained of deterioration in vision in his right eye since early childhood¹⁶. There have been few reports of microphthalmia with autosomal recessive inheritance^{10,17}. Bateman also reported three generations of dominantly inherited non-colobomatous microphthalmos¹⁸. Vingolo et al reported five generation pedigree with 14 subjects affected with bilateral microphthalmos not associated with other ocular or systemic signs³. The reported cases had microcornea³. These findings tally with our own and that of Weiss et al who reported the association of microcornea with a total length less than 18mm². Chukwuka et al reported a case of bilateral microphthalmos in Port Harcourt, Nigeria¹⁹ Just as in this case there was no other associated congenital anomaly in the former case.

The role of B scan ultrasonography in the management of patients with microphthalmos cannot be overemphasized. The introduction and recent advancement in ultrasonographic techniques²⁰ has allowed for accurate evaluation of the anterior and posterior segments of the eyes². The ultrasonography done in this patient actually contributed to the evaluation of the patient. In view of the challenging nature of the management of microphthalmos, there is need to work closely with the families of affected patients to ensure that the affected individuals are given adequate support. There is need for adequate antenatal care to prevent some congenital anomalies.

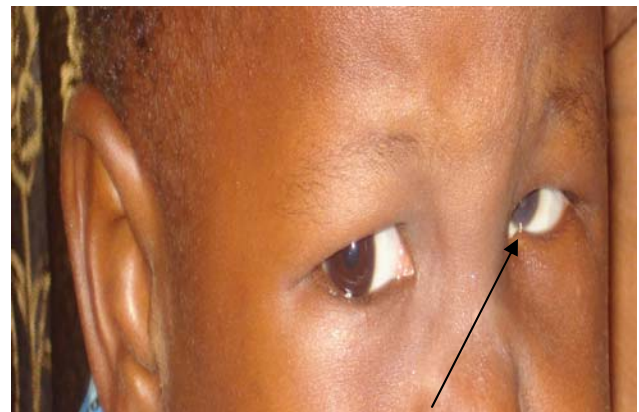


Fig. Child with left sided microphthalmos

Author's affiliation

C.O. Omolase
Department of Ophthalmology
Federal Medical Centre, Owo
Ondo State, Nigeria.

M.Y. Majekodunmi
Department of Ophthalmology
Federal Medical Centre, Owo
Ondo State, Nigeria

A.K. Akinwalere
Department of Ophthalmology
Federal Medical Centre, Owo
Ondo State, Nigeria

B.O. Omolase
Department of Radiology
Federal Medical Centre
Owo, Ondo State, Nigeria

REFERENCE

1. **Kim JW, Boes DA, Kinyoun JL.** Optical coherence tomography of bilateral posterior microphthalmos with papillomacular fold and novel features of retinoschisis and dialysis. *Am J Ophthalmol.* 2004; 138: 480-1.
2. **Weiss AH, Kousseff BG, Ross EA, et al.** Simple microphthalmos. *Arch Ophthalmol.* 1989; 107: 1625-30.
3. **Vingolo EM, Steindl K, Forte R, et al.** Autosomal dominant simple microphthalmos. *J Med Genet.* 1994; 31: 721-5.
4. **Frazer GR, Friedman AI.** The causes of blindness in childhood. Baltimore John Hopkins University Press. 1967; 59-60.
5. **Sjogren T, Larsson T.** Microphthalmos and anophthalmos with and without coincident oligophrenia. *Acta Psychiatr Neurol Scand.* 1949; 56: 1-103.
6. **Zeiter HJ.** Congenital microphthalmos. Apedigree of four affected siblings and additional report of forty four sporadic cases. *Am J Ophthalmol.* 1963; 55: 910-22.
7. **Guyer DR, Green WR.** Bilateral extreme microphthalmos. *Ophthalmic Paediatr Genet.* 1984; 4: 81-90.
8. **Ghose, Singh NP, Kaur D et al.** Microphthalmos and anterior segment dysgenesis in a family. *Ophthalmic Paediatr Genet.* 1991; 12: 177-82.
9. **Khairallah M, Messaoud R, Zaouali S, et al.** Posterior segment changes associated with posterior microphthalmos *Ophthalmology.* 2002; 109: 569-74.
10. **Spitznas M, Gerke E, Bateman JB.** Hereditary posterior microphthalmos with papillomacular fold and high hyperopia. *Arch Ophthalmol.* 1983; 101: 413-17.
11. **Krastionova D, Kelly MB, Mihaylova M.** Surgical management of the anophthalmic orbit, Part 1: Congenital Plast Reconstr Surg. 2001; 108: 817-26.
12. **Dolk H, Busby A, Armstrong BG.** Geographical variation in anophthalmia in England. 1988-94 *BMJ* 1998; 317: 905-9.
13. **O'Keefe M, Webb M, Pashby RC, et al.** Clinical anophthalmos. *Br J Ophthalmol.* 1987; 71: 635-8.
14. **Meenken C, Assies J, Van Nieuwenhuizen O, et al.** Longterm ocular neurological involvement in severe congenital toxoplasmosis. *Br J Ophthalmol.* 1995; 79: 581-4.
15. **Tsutsui Y, Kashiwai A, Kawamura N, et al.** Microphthalmia and cerebral atrophy induced in mouse embryos by infection with murine cytomegalovirus in midgestation. *Am J Pathol.* 1993; 143: 804-13.
16. **ChenMS, Ho TC, Chang CC, et al.** Retinal detachment in a patient with microphthalmos and choroidal coloboma. *J Formos Med Assoc.* 2007; 106: 965-8.
17. **Fledelius HC, Rosenberg T.** Extreme hypermetropia and posterior microphthalmos in three siblings .An oculo metric study In: Ossoing KC, Nijhoff M, eds. *Ophthalmic echography.* Dordrecht: NJ Junk. 1987: 87-91.
18. **Bateman JB.** Microphthalmos. *Int Ophthalmol Clin.* 1984; 24: 87-107.
19. **Chukwuka IO, Pedro-Egbe CN.** Bilateral congenital microphthalmos *Port Harcourt Medical Journal.* 2008; 2: 278-281.
20. **Stewart DH, Streeten BH, Bockhurst RJ, et al.** Abnormal sclera collagen in nanophthalmos. An ultrastructural study *Arch Ophthalmol.* 1991; 109: 1017-25.